Role of Entrainment in the Era of High-Density Activation Mapping

Pasquale Santangeli MD PhD
University of Pennsylvania Health System
Philadelphia, PA

Penn
UNIVERSITY of PENNSYLVANIA

Presenter Disclosure Information

Within the past 12 months, the presenter has received financial support from the organizations identified below for the relationships listed.

Company Name: *	Relationship:
Biosense Webster	Consultant / Lecture Honorarium
Baylis Medical	Consultant / Lecture Honorarium
Boston Scientific	Consultant / Lecture Honorarium
St. Jude Medical	Consultant
Stereotaxis	Consultant / Lecture Honorarium
Abiomed	Consultant

*No organization has prepared, altered or influenced content of any lecture material

What is the Holy Grail for VT Ablation?

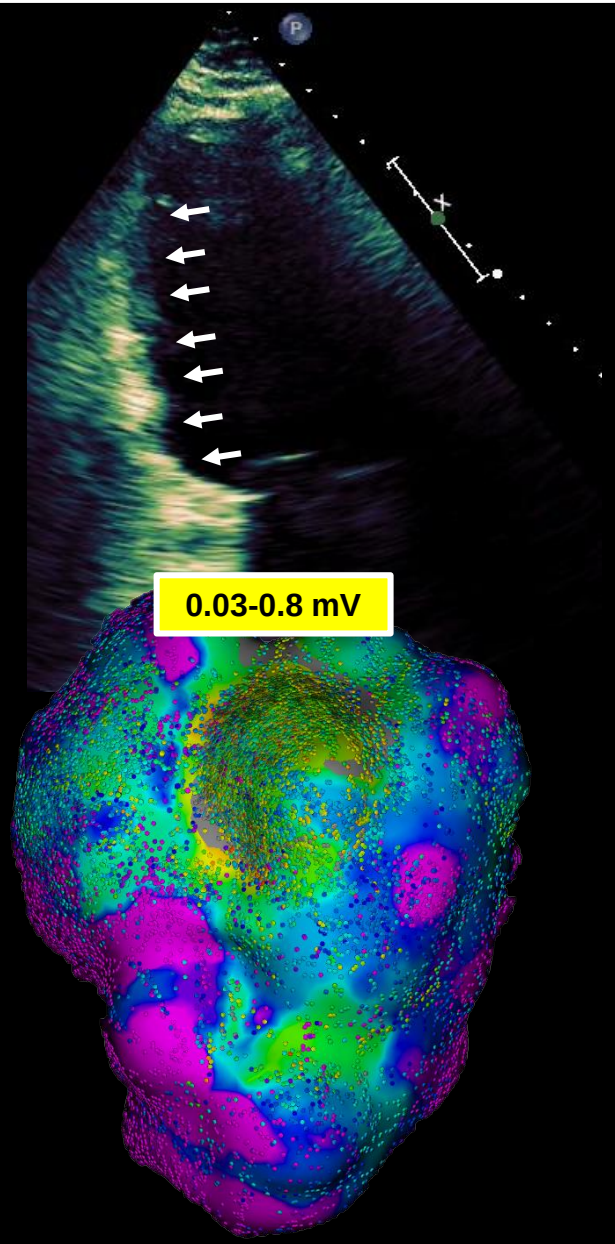

What is the Holy Grail for VT Ablation?

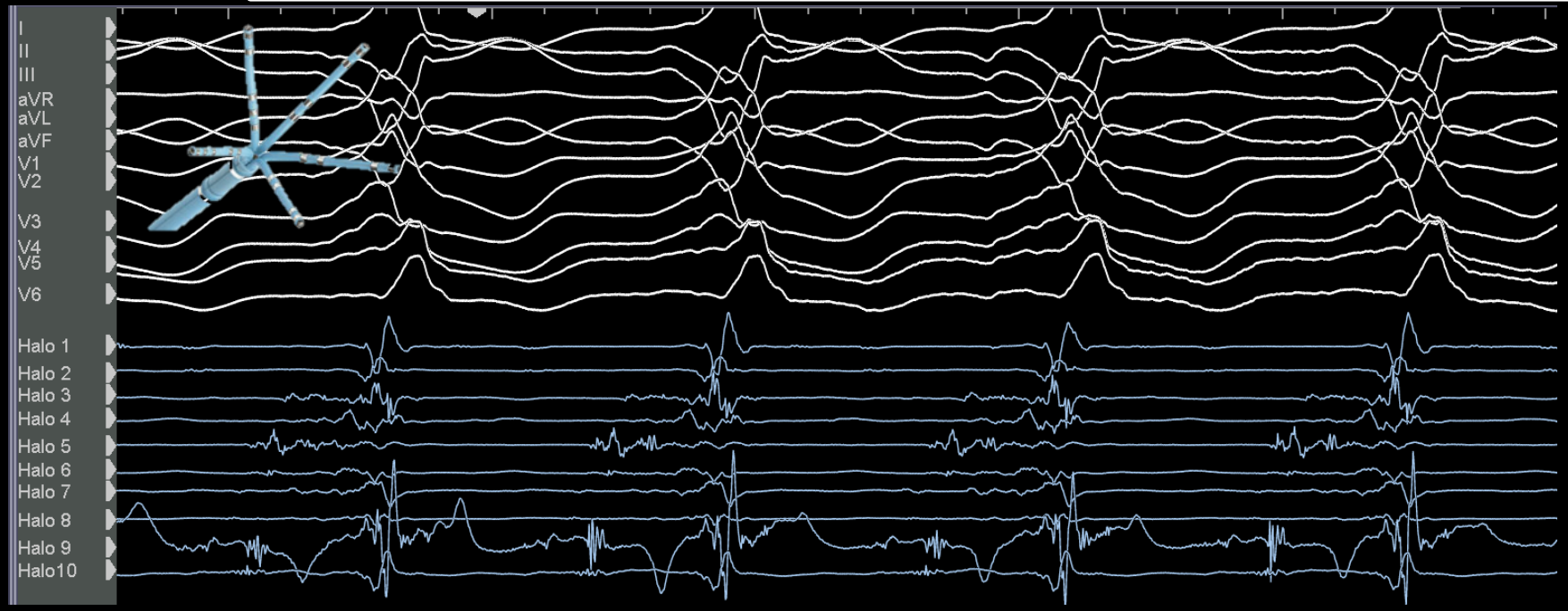

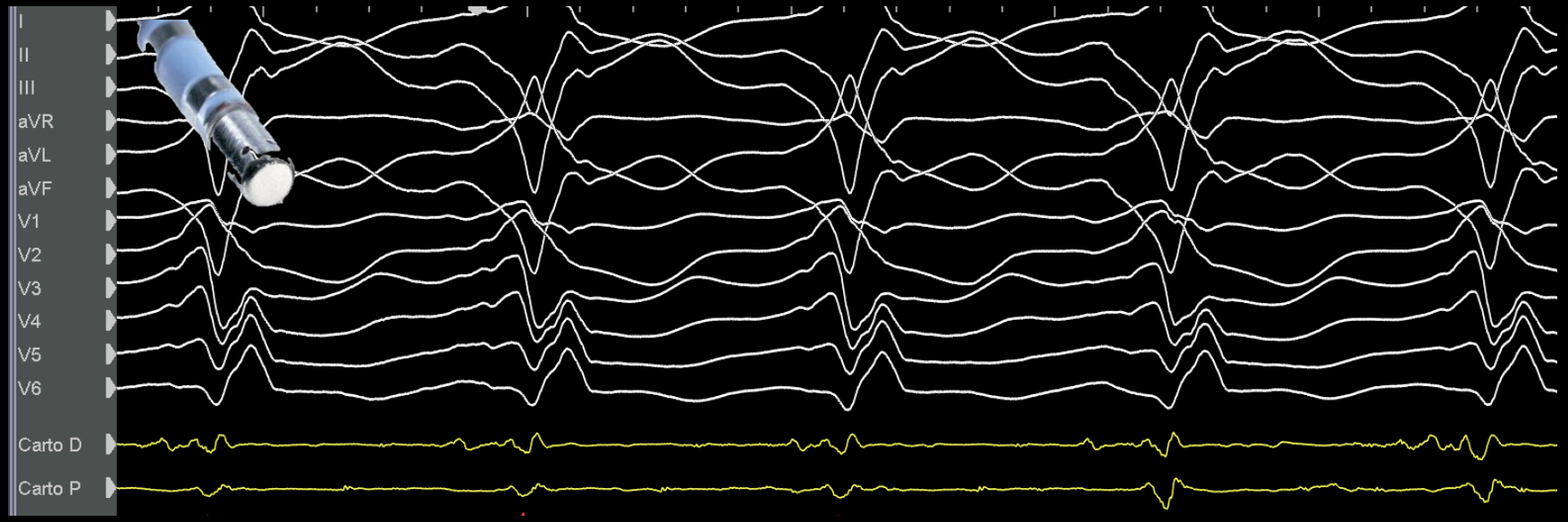

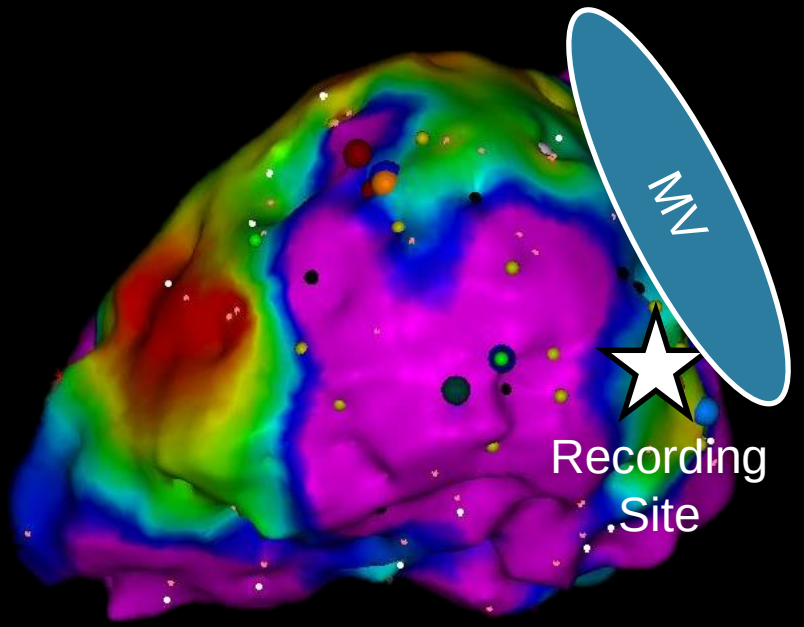

What is the Holy Grail for VT Ablation?

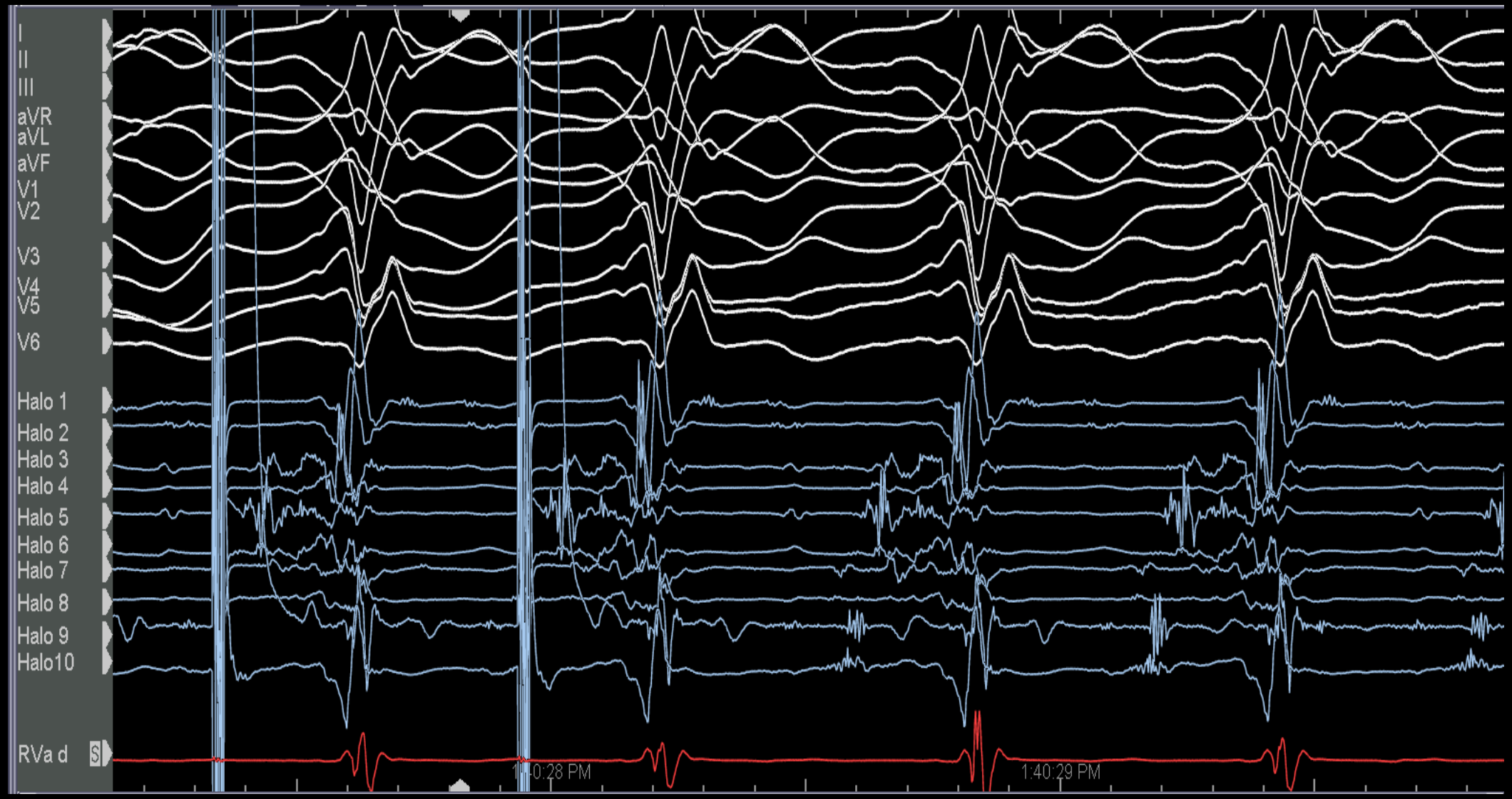

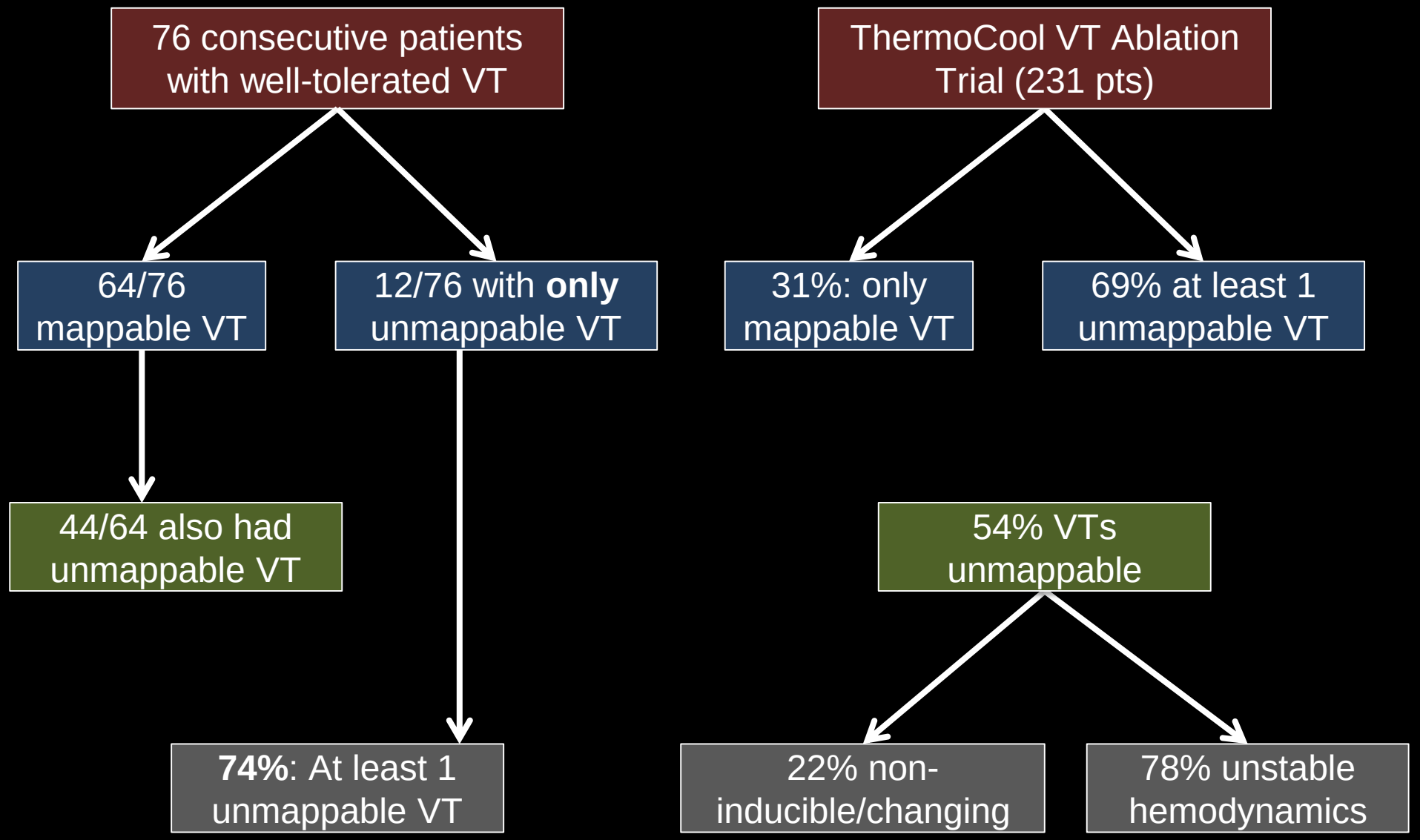

Callans et al. AJC 1998;82:429-432

Stevenson et al. Circulation 2008;118:2773-2782

Ability to Map VT

Arrhythmia Specific and Patient Specific Factors

2,063 patients with scar-related VT

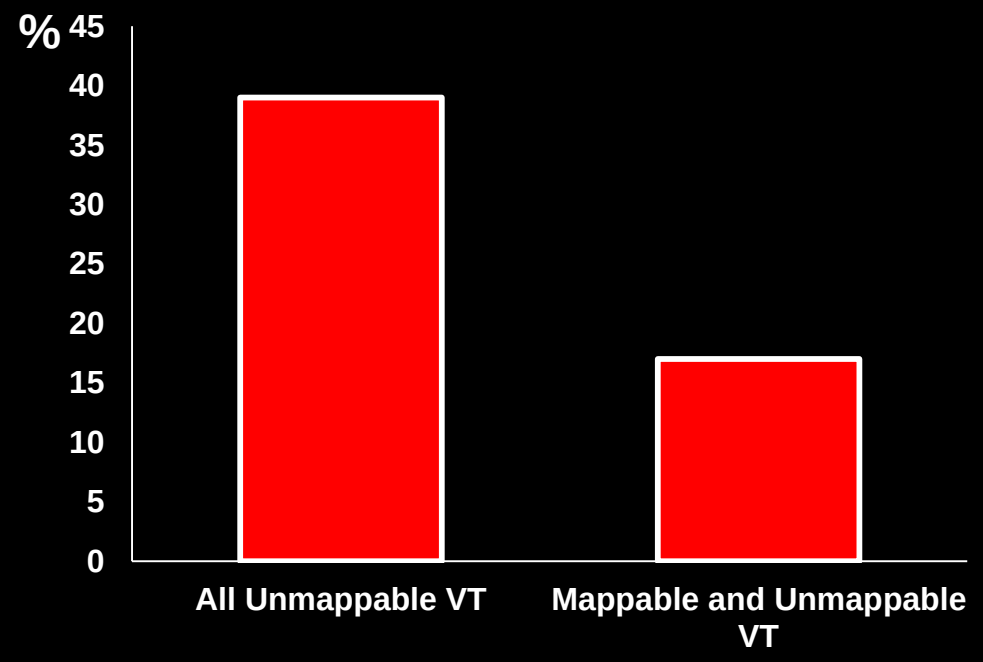

Acute Hemodynamic Decompensation (AHD)*



PAINESD RISK SCORE

VARIABLE	SCORE
Pulmonary disease [COPD]	5
Age >60 years	3
Anesthesia [general]	4
Ischemic cardiomyopathy	6
NYHA class III or IV	6
Ejection fraction <25%	3
Storm [VT]	5
Diabetes mellitus	3

***Sustained hypotension (SBP<80-90 mmHg) despite increasing doses of vasopressors and requiring mechanical hemodynamic support or procedure discontinuation.**

Santangeli et al. JACC 2017;69:2105-2115
Santangeli et al. Circulation A&E 2015;8:68-75

Mappable VTs – Preferred Strategy?

High-Density Activation Mapping vs. Entrainment Mapping

- 62 yo M h/o CAD (inferior MI), HTN, mild CKD.
- 8 ICD shocks – incessant stable MMVT at 140 bpm.
- TTE: Severe LV dysfunction (EF = 35%), inferior-lateral akinesis.
- SPECT : Large fixed defect in the inferior-lateral wall base to apex. EF = 30%.

Substrate

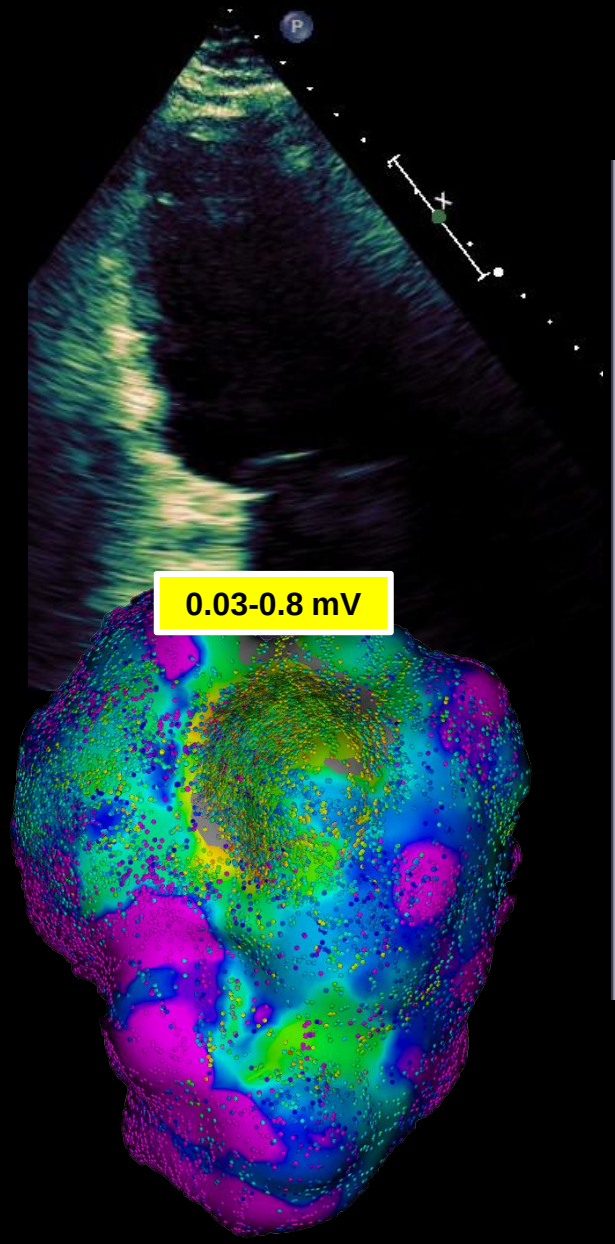

12-Lead ECG of VT

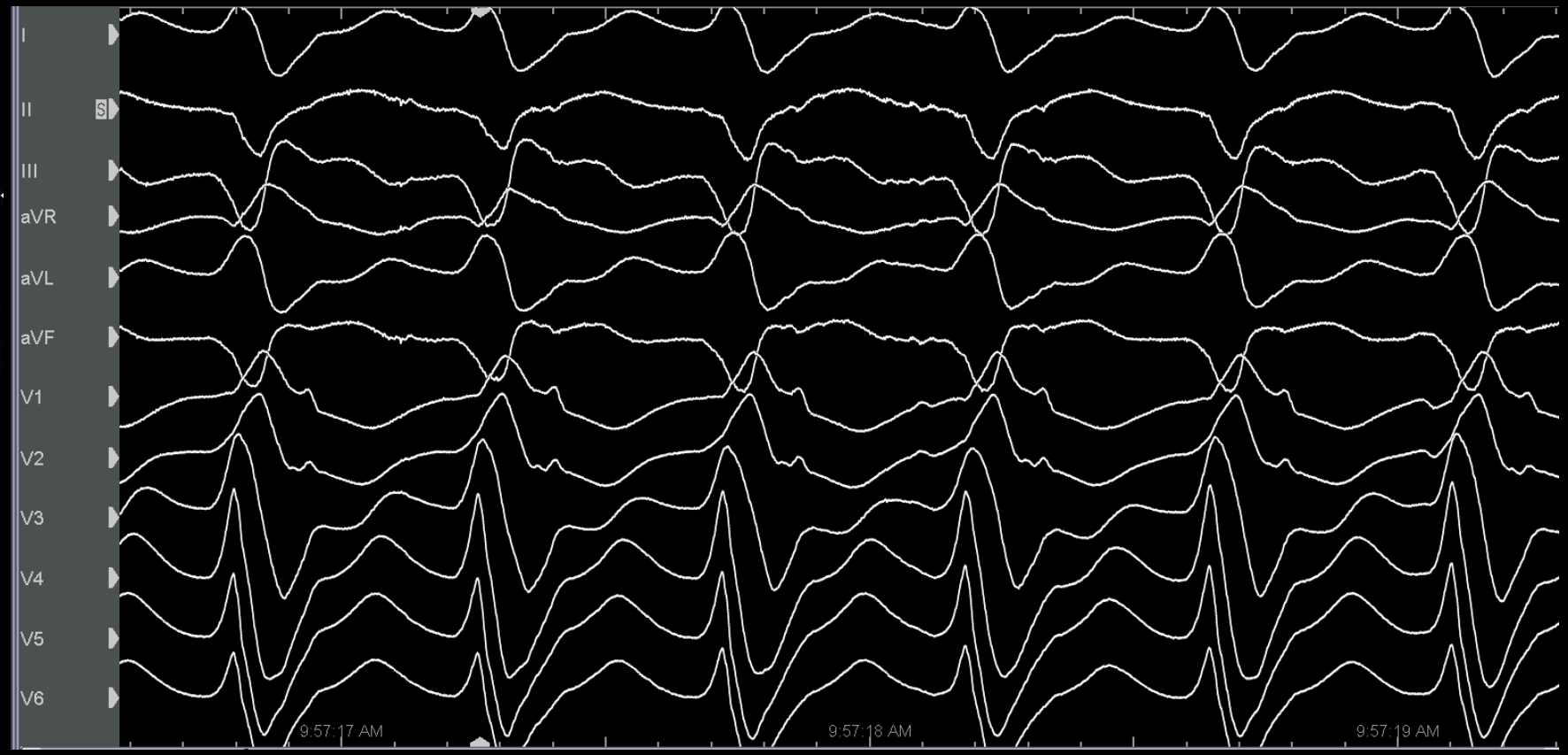

High-Density Activation Map

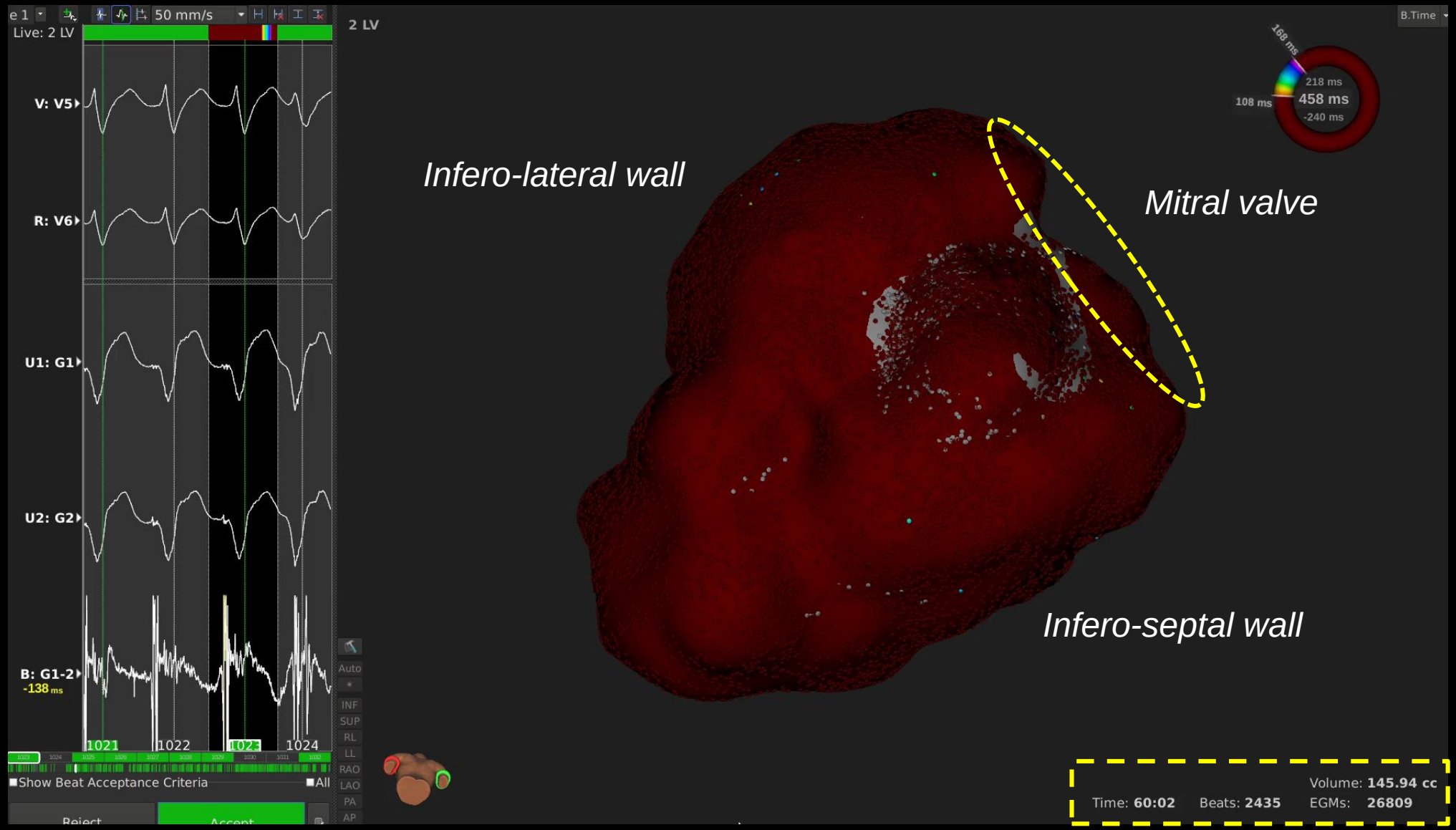

Where Would You Ablate?

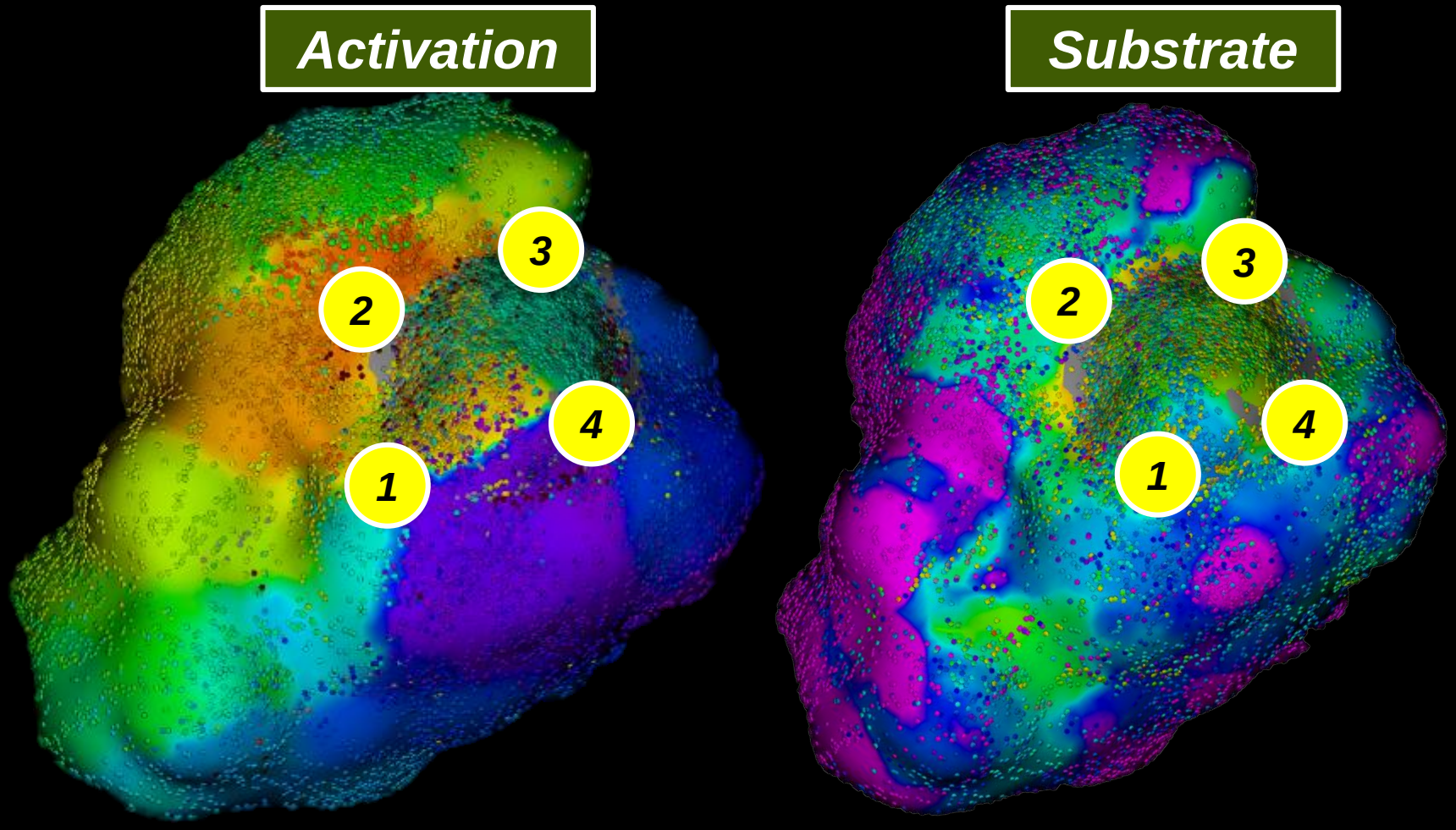

- *Site #1*
- *Site #2*
- *Site #3*
- *Site #4*

Voltage Scale 0.03 to 0.5 mV

High-Density Activation Map vs. Entrainment

Critical Site of VT Termination

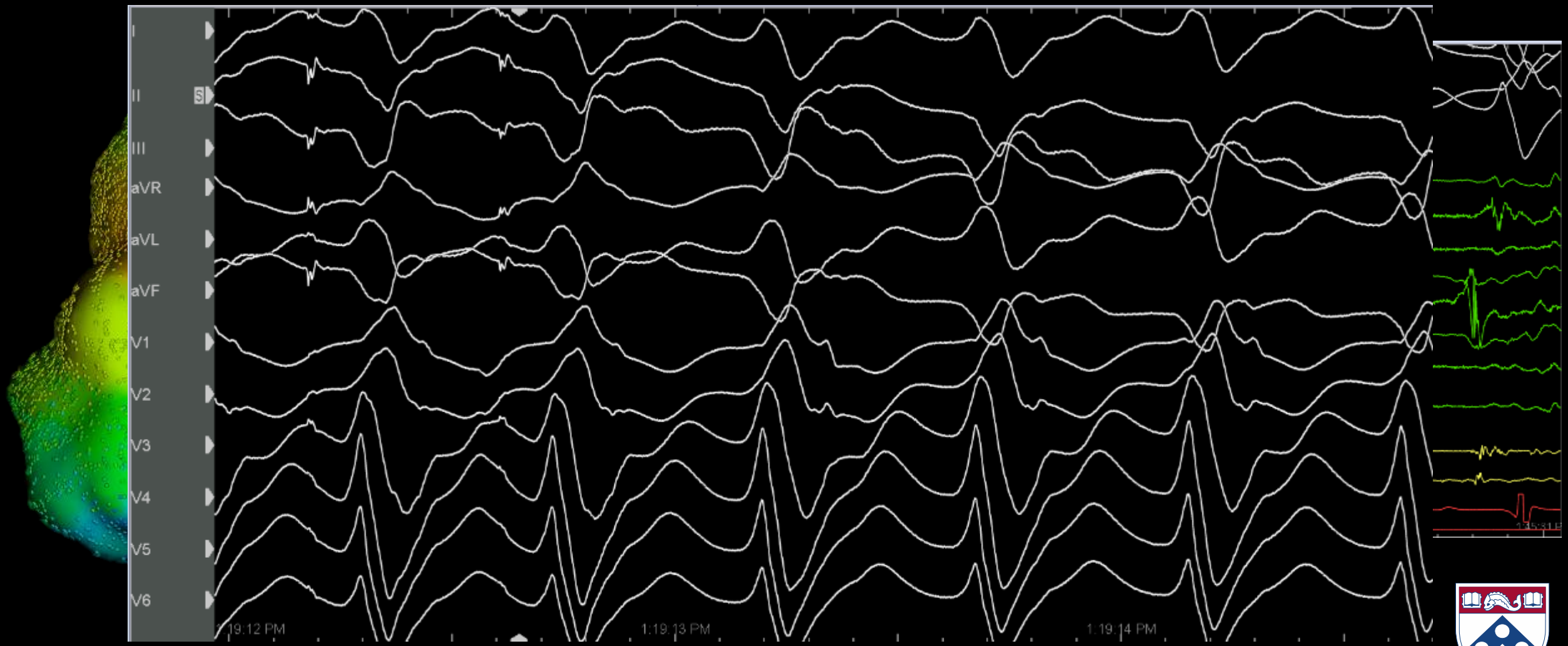

Visual Reentry Can Be Passive

15 pts w/ 27 RA reentrant circuits

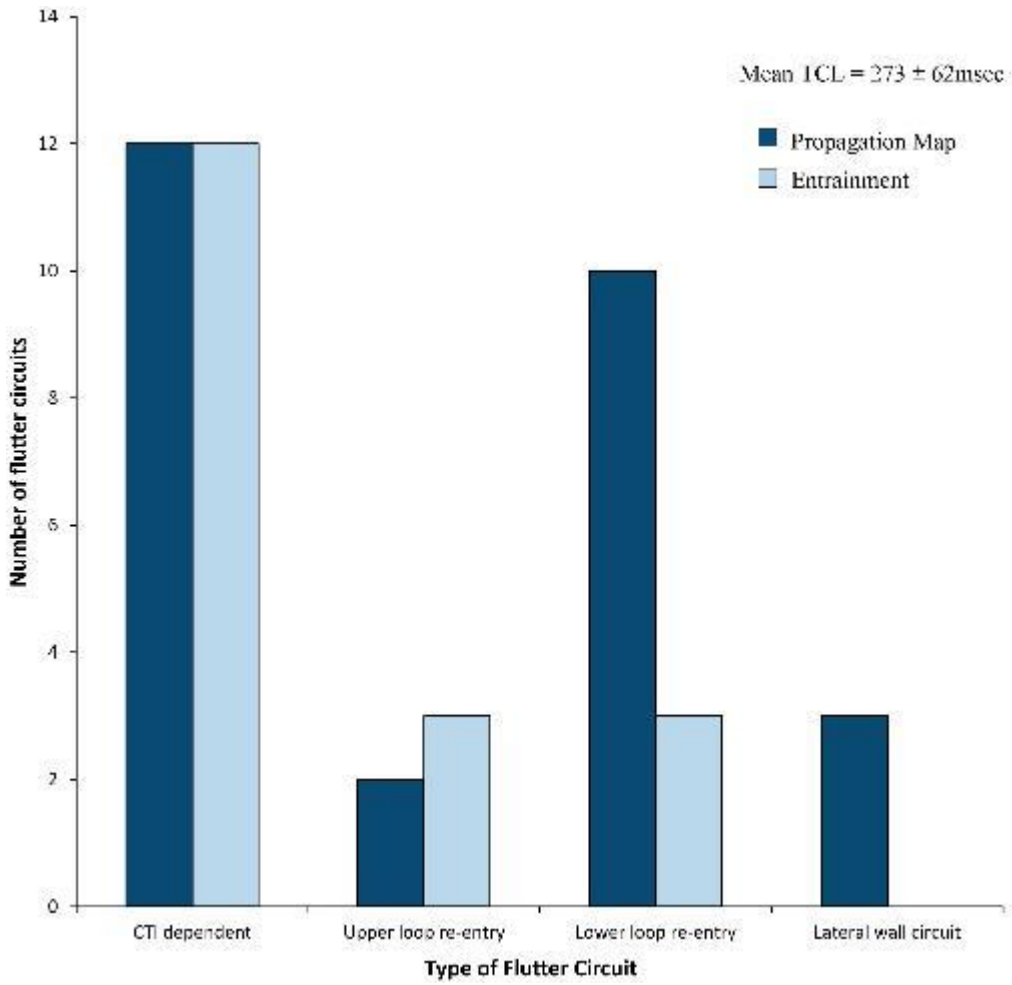

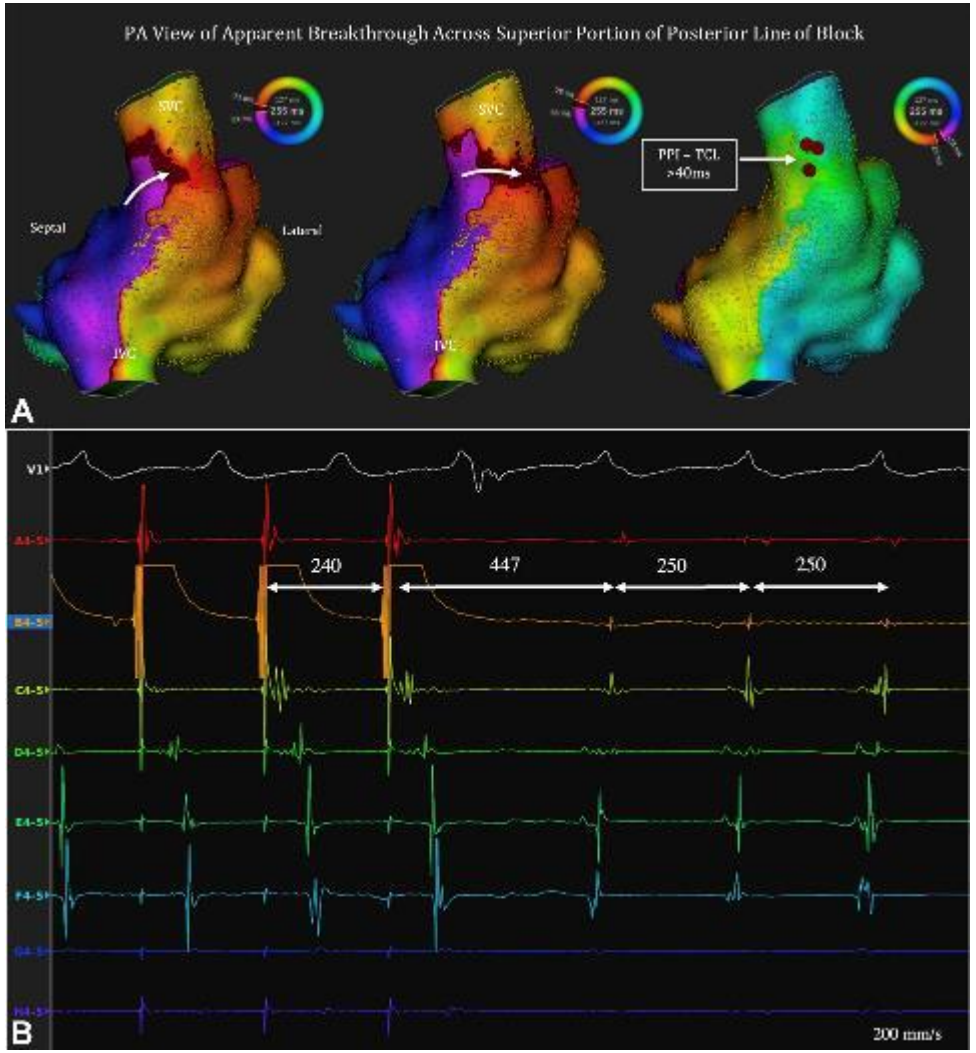

Pathik et al. Heart Rhythm 2017;14:1541-49

Visual Reentry Can Be Passive

None of the entrainment runs resulted in termination of AT or change to a different AT

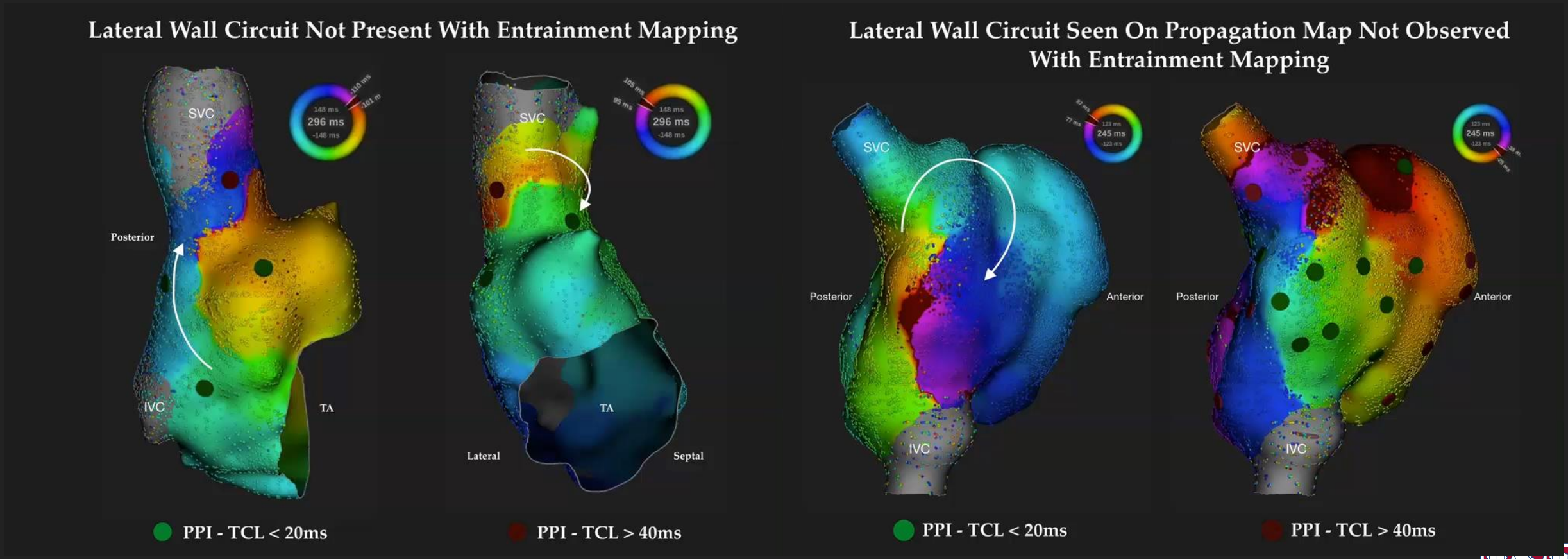

Pathik et al. Heart Rhythm 2017;14:1541-49

Activation Mapping to Define VT Mechanism?

42 yo F w/ ARVC and Incessant VT

VT

Activation Map

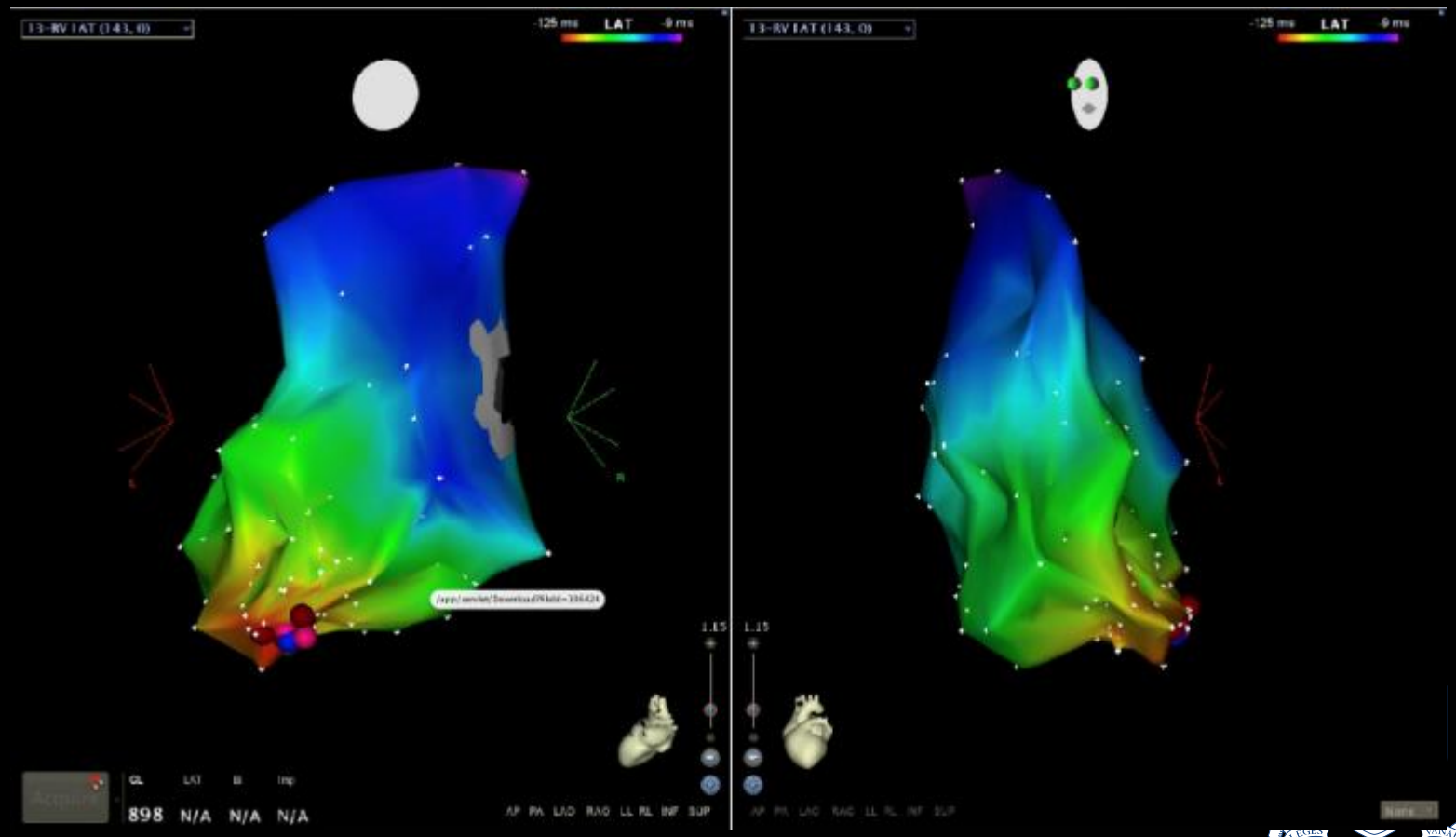

Quick Definition of VT Mechanism w/ Pacing

42 yo F w/ ARVC and Incessant VT

Fully Paced

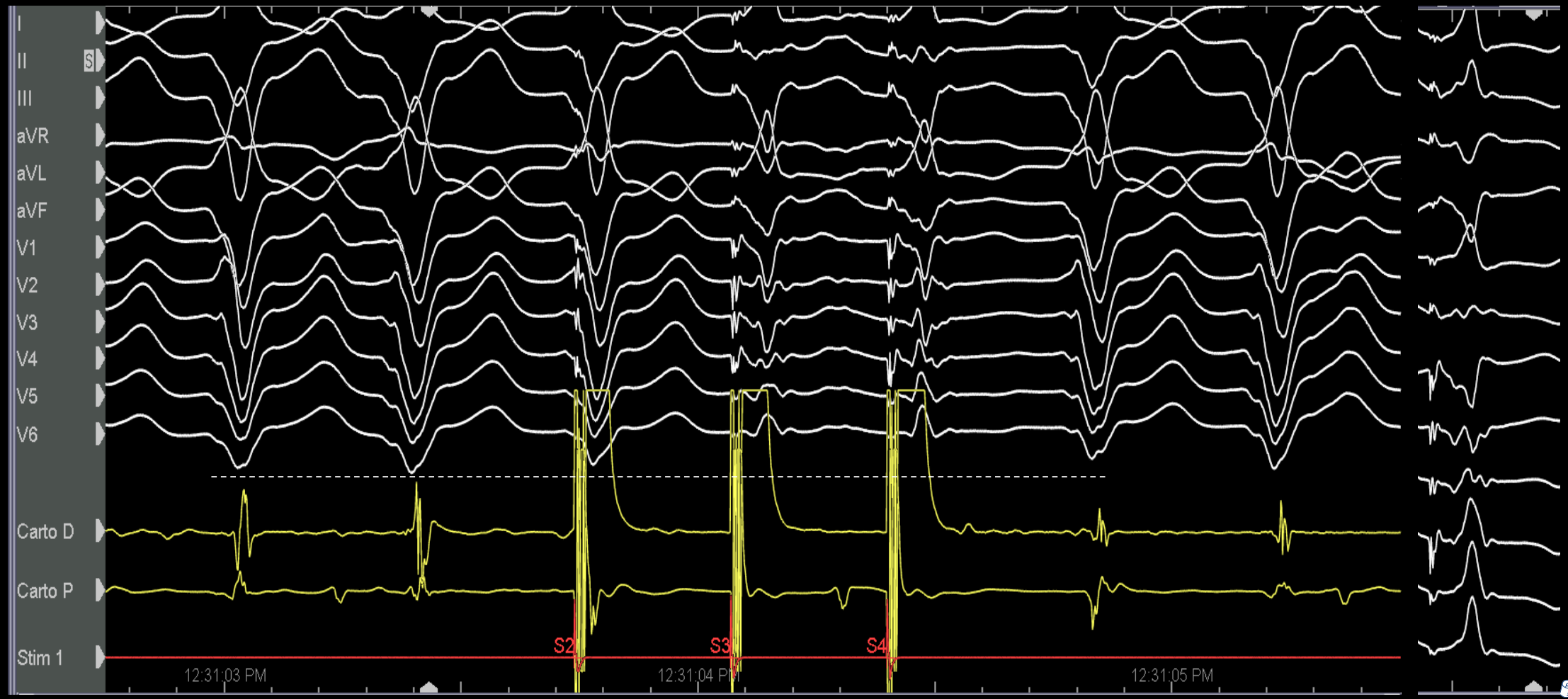

Fully VT

Progressive fusion

Fully Paced

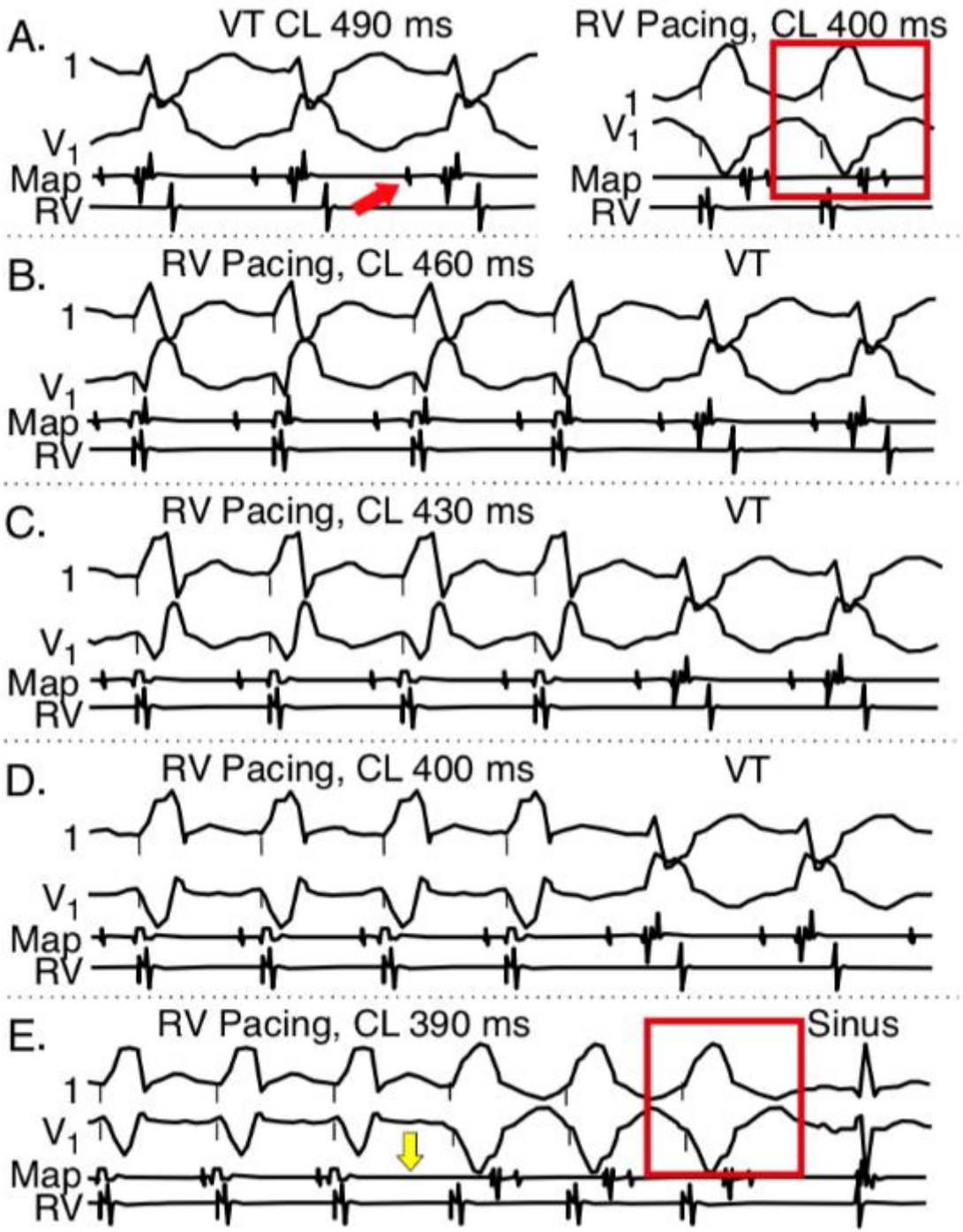

Unequivocal Definition of Critical Diastolic Components w/ Entrainment

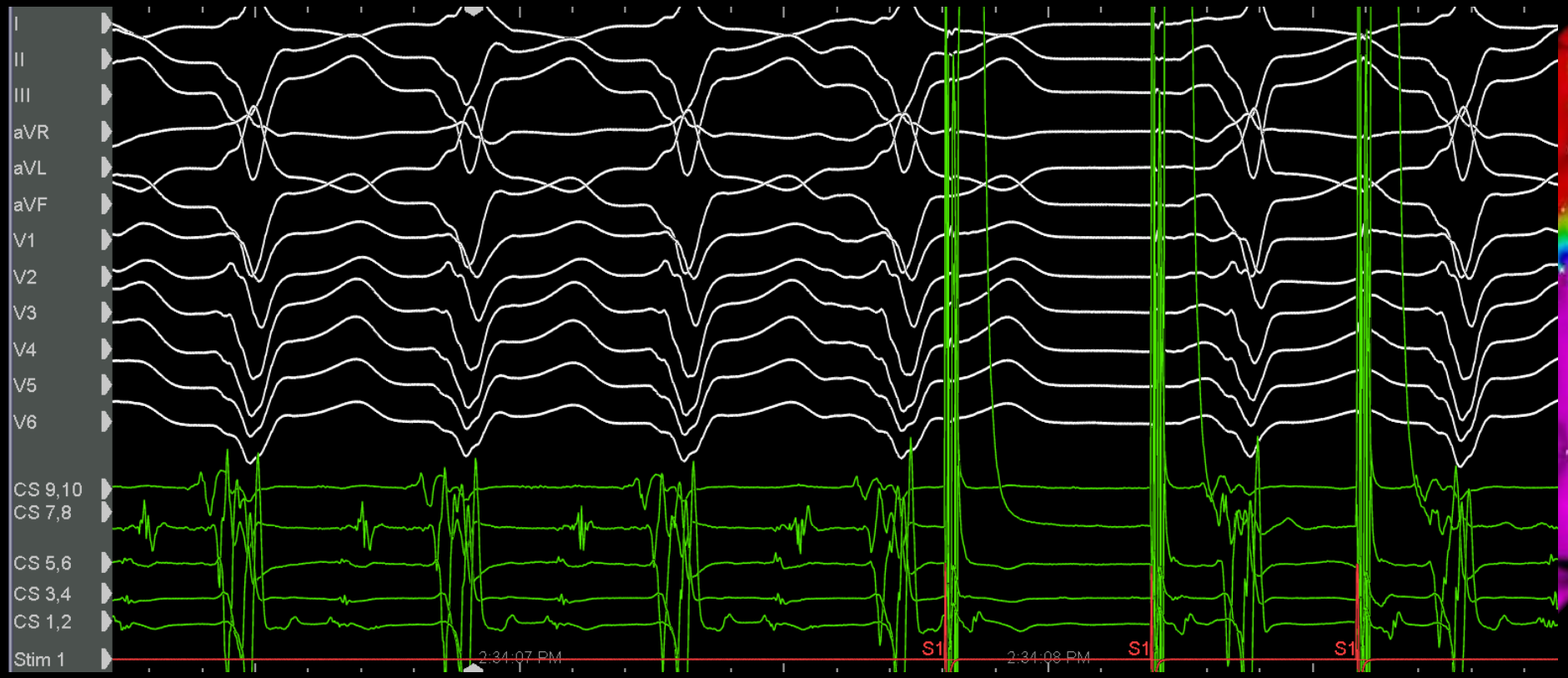

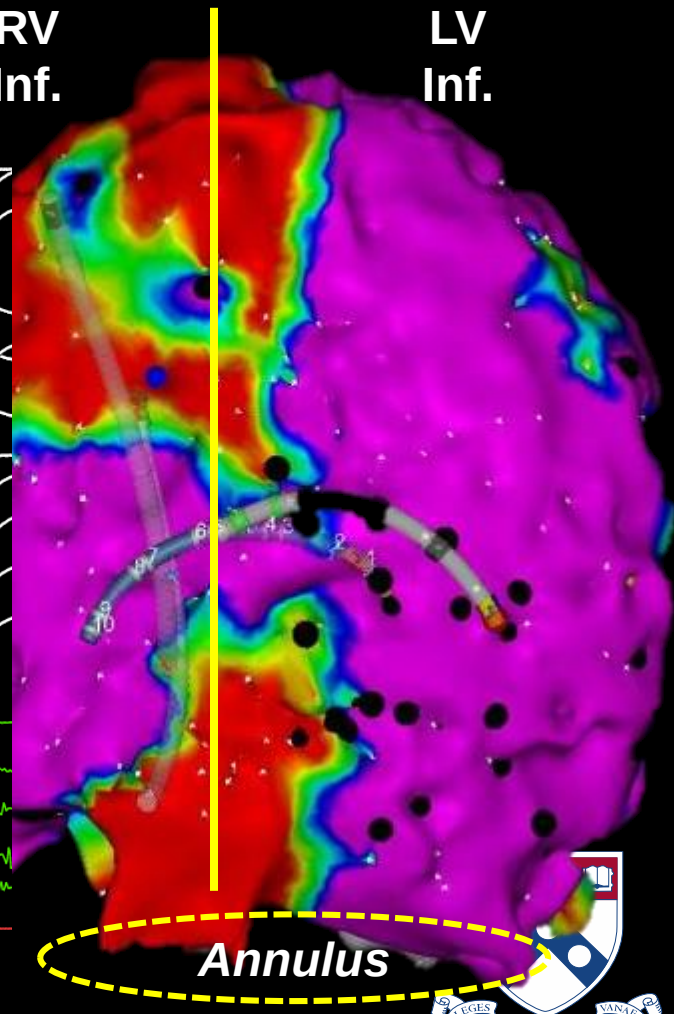

Unequivocal Definition of Critical Diastolic Components w/ Entrainment

High-Density Activation Mapping
Limitations

- Highly dependent on sampling bias (full chamber/cycle length needs to be represented)
- Unable to reliably differentiate passive diastolic activity from diastolic activity participating to VT.
- Unable to differentiate true reentry from focal origin adjacent to a line of block (anatomical or functional).
- Only adequate to define circuits when reentry is confined within a fully mappable chamber/structure (2-D/surface reentry).

Reentry *Is Not* Necessarily Confined to Mappable Surface

52 yo M with Antero-Lateral MI

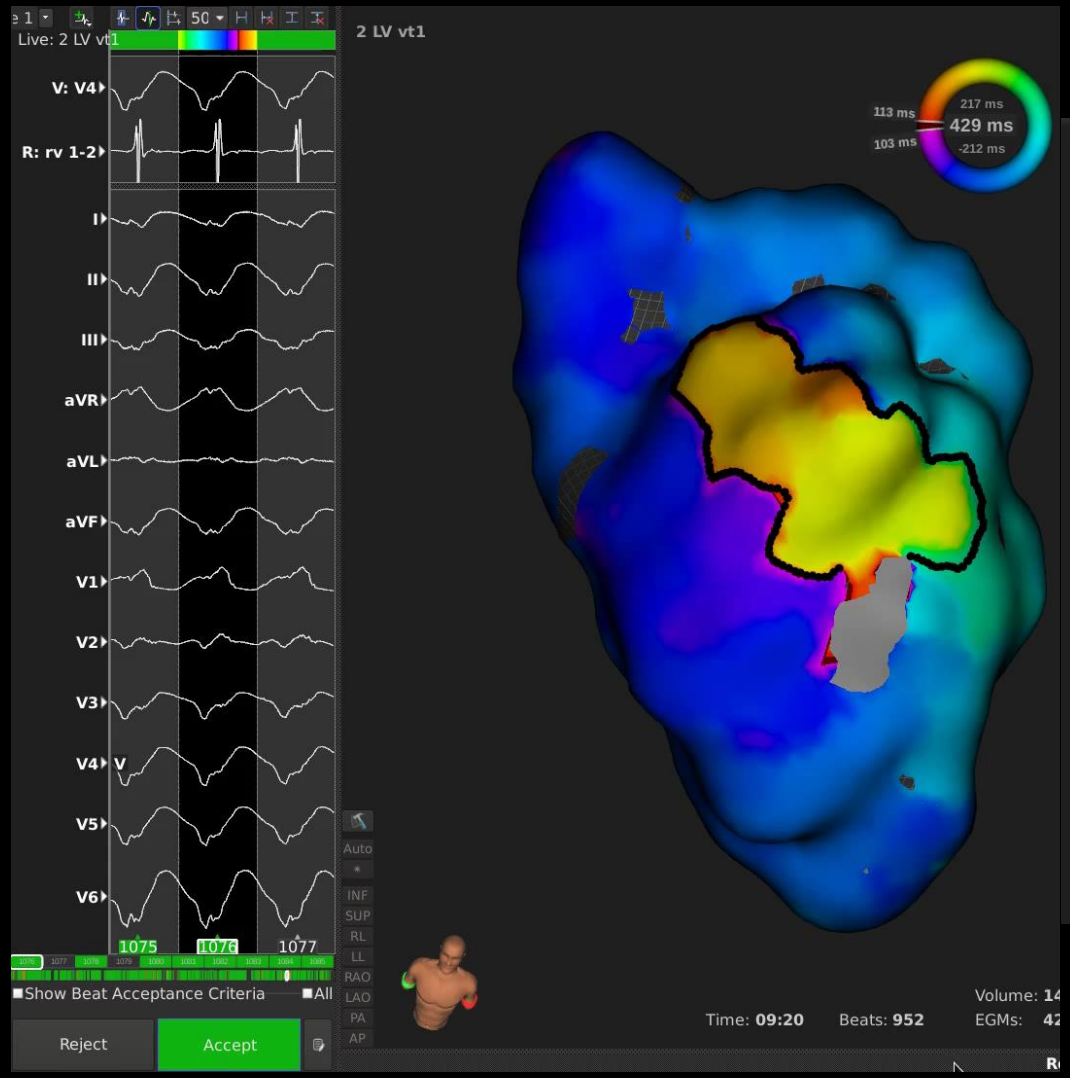

Courtesy of Drs. Paolo Della Bella and Caterina Bisceglia

Entrainment Mapping *Is Not* Perfect!

- Unable to reliably capture with a fixed relationship of stimulus to EGMs.
- Non-local recording and non-local stimulation – particularly with large interelectrode distance and/or large tip electrode.
- Contact with tissue generating signal.
- Obscuring EGM by pacing artifact.
- Termination/change during pacing.
- High current produces non-local stimulation (enlarged virtual electrode).

Failure to Capture

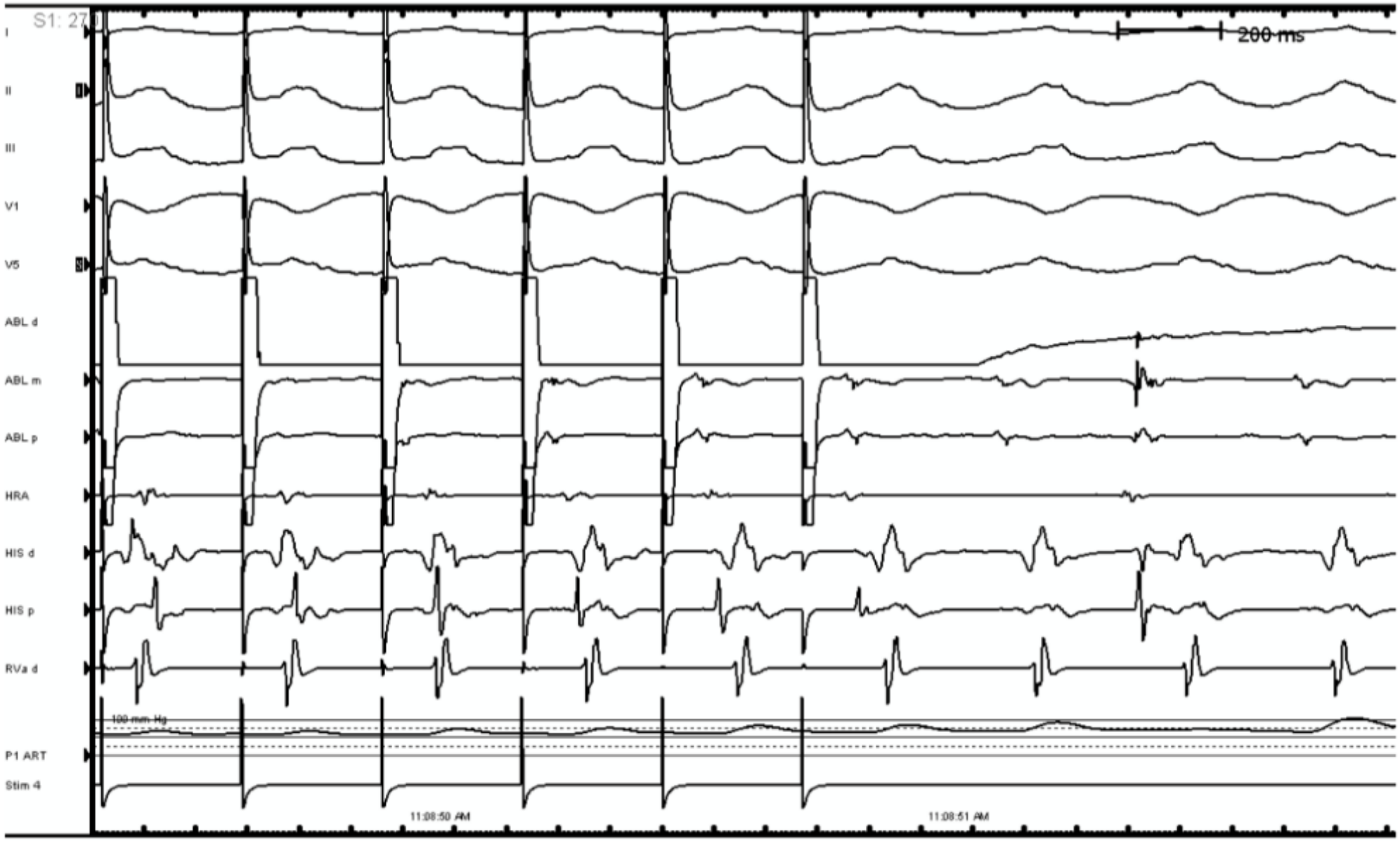

Need *Perfect* ECG Match – *RF Failed to Terminate*

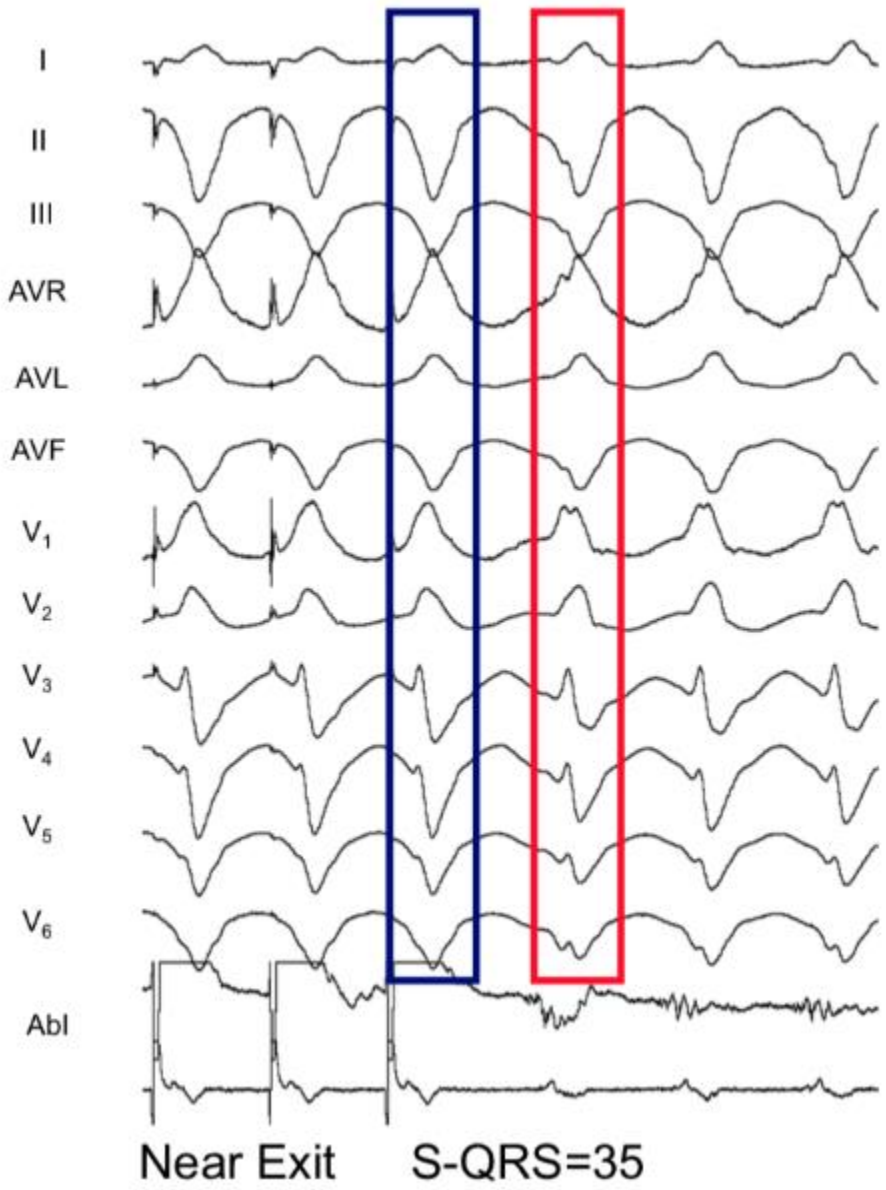

Good Entrainment Map – *12/12 Perfect Match*

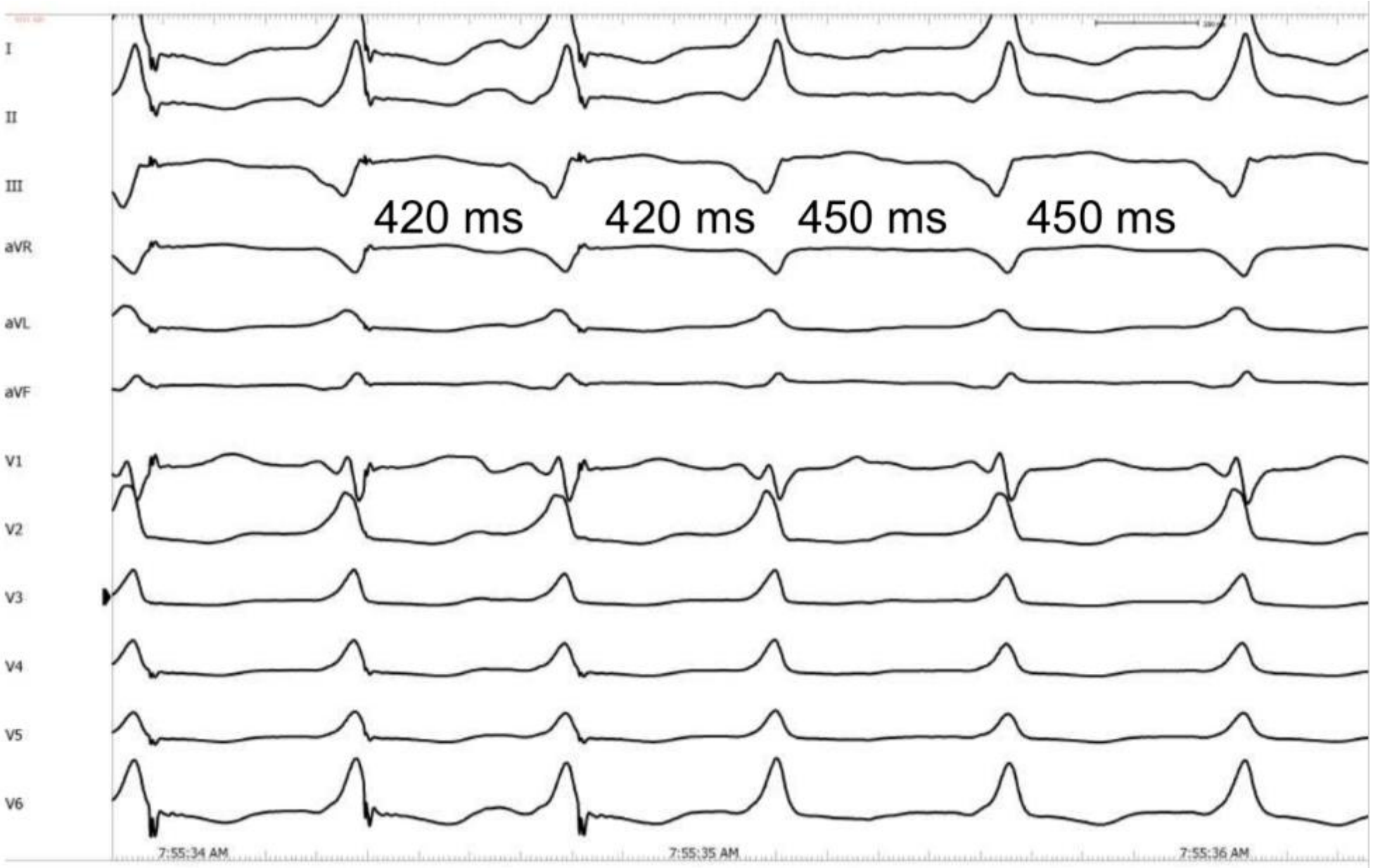

Good Entrainment Map – *PPI-TCL=0*

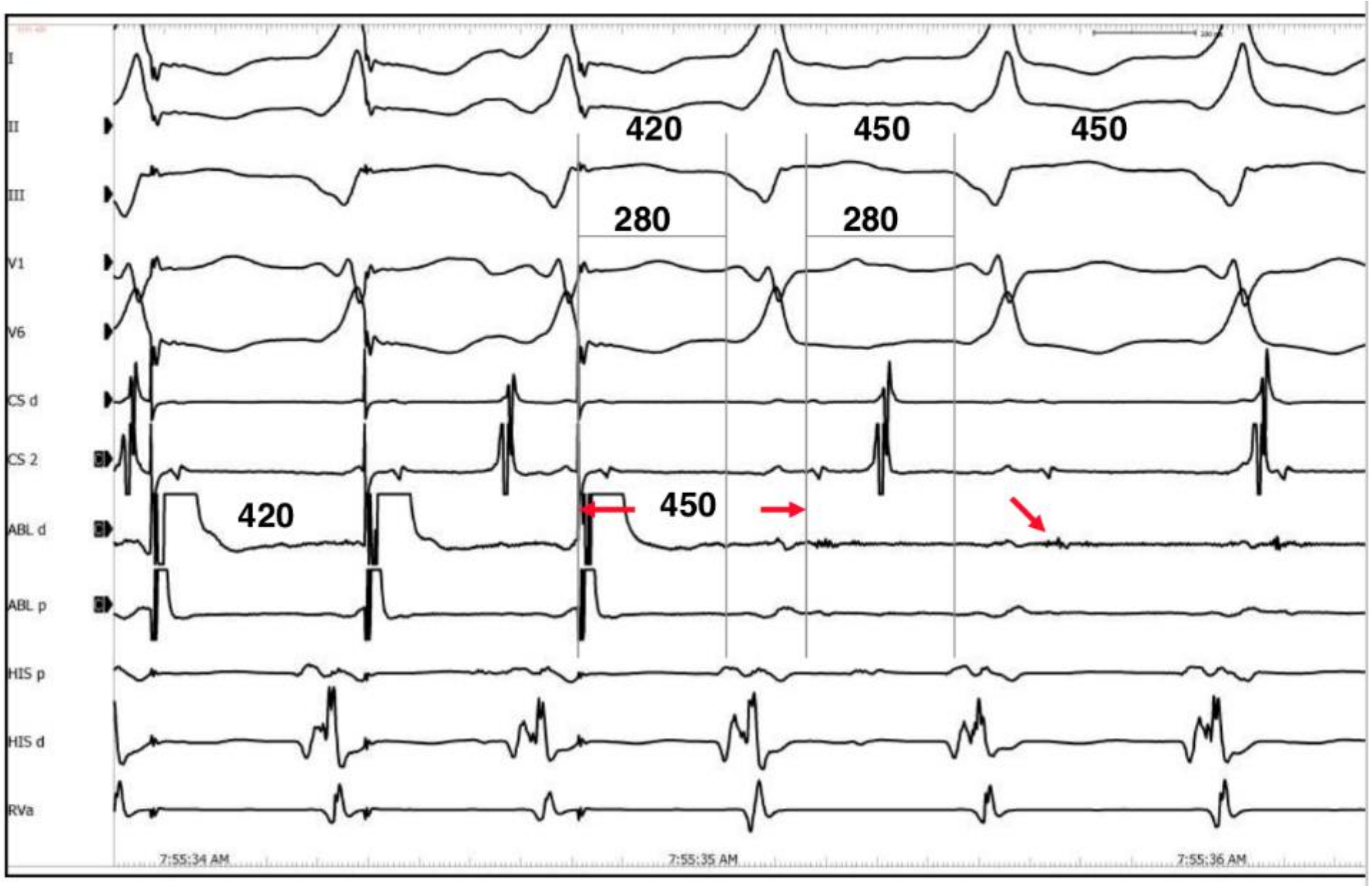

Failure to Terminate VT at a Single Site Despite *Apparent* Perfect Entrainment Map

- Inadequate map
- Inadequate lesion
  - Clot/Fat/Scar
  - Deep location of VT (intramural)
  - Width of isthmus exceeds RF point lesion

Entrainment Mapping in the Era of High-Density Activation Mapping - *Conclusions*

- When a stable monomorphic VTs is present use of responses to pacing, based on *physiologic principles*, can define critical sites in the circuit (i.e. a protected isthmus).
- Although high-density activation mapping may be helpful to identify reentrant excitation and *visually define* regions of diastolic activity, it is unnecessary (and possibly misleading) in identifying critical diastolic sites at which RF lesions can terminate VT.